

# Journal of Biomedical Optics

[SPIEDigitalLibrary.org/jbo](http://SPIEDigitalLibrary.org/jbo)

## **Laser scoop desobliteration: a method for minimally invasive remote recanalization of chronically occluded superficial femoral arteries**

Carola Heneweer  
Markus Siggelkow  
Michael Helle  
Rainer Petzina  
Asmus Wulff  
Joost P. Schaefer  
Rouven Berndt  
Rene Rusch  
Thilo Wedel  
Guenther Klaws  
Magdalena Müller-Gerbl  
Christoph Röcken  
Olav Jansen

# Laser scoop desobliteration: a method for minimally invasive remote recanalization of chronically occluded superficial femoral arteries

Carola Heneweer,<sup>a</sup> Markus Siggelkow,<sup>b</sup> Michael Helle,<sup>a,c</sup> Rainer Petzina,<sup>b</sup> Asmus Wulff,<sup>a</sup> Joost P. Schaefer,<sup>a</sup> Rouven Berndt,<sup>b</sup> Rene Rusch,<sup>b</sup> Thilo Wedel,<sup>d</sup> Guenther Klaws,<sup>d</sup> Magdalena Müller-Gerbl,<sup>e</sup> Christoph Röcken,<sup>f</sup> Olav Jansen,<sup>a</sup> Georg Lutter,<sup>b</sup> Joachim Cremer,<sup>b</sup> and Justus Groß<sup>b,\*</sup>

<sup>a</sup>University Medical Center Schleswig-Holstein, Clinic of Radiology and Neuroradiology, Arnold-Heller-Street 3, 24105 Kiel, Germany

<sup>b</sup>University Medical Center Schleswig-Holstein, Clinic of Cardiovascular Surgery, Arnold-Heller-Street 3, 24105 Kiel, Germany

<sup>c</sup>Philips GmbH Innovative Technologies, Research Laboratories, Roentgenstr. 24-26, 22335 Hamburg, Germany

<sup>d</sup>Christian-Albrechts-Universität zu Kiel, Institute of Anatomy, Otto-Hahn Platz 8, 24118 Kiel, Germany

<sup>e</sup>University of Basel, Department of Biomedicine, Pestalozzistr. 20, 4056 Basel, Switzerland

<sup>f</sup>University Medical Center Schleswig-Holstein, Institute of Pathology, Arnold-Heller-Str. 3, 24105 Kiel, Germany

**Abstract.** Stenosis and occlusion of the superficial femoral artery (SFA) are most common in arterial occlusive disease. There are numerous interventional, surgical, and combined approaches to reconstitute maximum blood supply to the lower limb; however, despite intense clinical research, the long-term success rates are still poor. We present the first results with a catheter prototype for laser-based minimal invasive endarterectomy, called laser scoop desobliteration (LSD). The tip of a glass fiber containing a catheter was modified with a spatula head design and connected to an ultraviolet laser. It was tested in cadavers fixed with the Thiel embalming technique preserving tissue consistency, flexibility, and plasticity. After longitudinal arteriotomy of the SFA, a circular dissection between media and adventitia was performed. Then the LSD catheter was inserted and propagated with a progress of 1 mm/s. Afterward, the atheroma core, which showed a plain surface without substantial attaching tissue debris, was removed. Histological examination of the vessel wall showed that the dissection was performed at the media/adventitia interface. In summary, the constructed LSD catheter allowed a rapid and easy way to perform an endarterectomy, thereby offering an innovative approach in the treatment of chronic occluded SFA. © 2015 Society of Photo-Optical Instrumentation Engineers (SPIE) [DOI: 10.1117/1.JBO.20.2.025005]

Keywords: vascular surgery; peripheral arterial disease; superficial femoral artery; occlusion; laser; endarterectomy.

Paper 140443TNR received Aug. 28, 2014; accepted for publication Jan. 19, 2015; published online Feb. 19, 2015.

## 1 Introduction

Peripheral arterial disease (PAD) is one of the main reasons for morbidity and mortality in the older patient population. In Germany, it shows a prevalence of about 8%. About 5% of these patients lose their limbs, which equals about 50,000 amputations per year. The prevalence increases with age. While only 6% of the 45- to 55-year-old patients suffer from PAD, the prevalence increases to >30% above the age of 65 years.<sup>1,2</sup> Since PAD is accompanied by a high morbidity, loss of quality of life, as well as loss of autonomy in everyday life, it will become a sociomedical and medicoeconomic problem in the future, especially with the prospect of a continuously aging population.

The most common localization for peripheral arterial occlusive disease is the femoropopliteal region resulting in claudication, ischemic rest pain, and ultimately ulceration or gangrene of the lower limbs. Different therapy strategies exist for different vascular territories. Each of these revascularization methods and techniques has specific advantages, disadvantages, and significant reconstruction rates. Thus, all available techniques comprise certain limitations in use.<sup>3,4</sup>

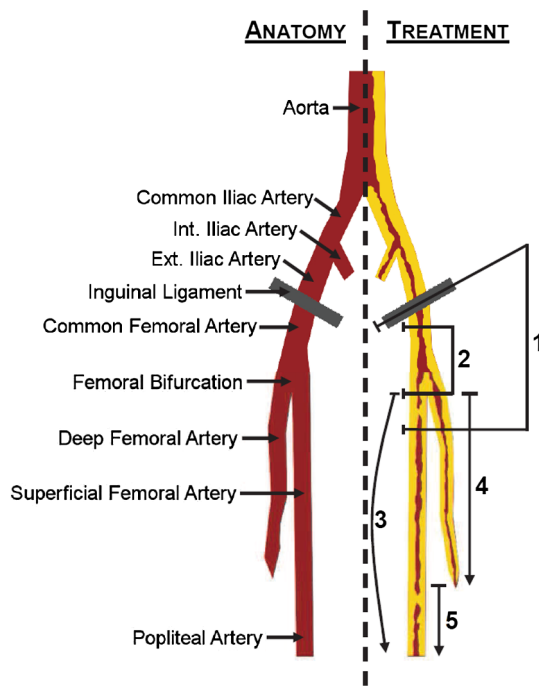
Endarterectomy of the femoral bifurcation is the gold standard for treatment of the proximal femoropopliteal region with

patency rates of nearly 95% after 3 years and 89% after 5 years in long-term reviews<sup>4</sup> (Fig. 1).

The downstream femoropopliteal region with the superficial femoral artery (SFA) is affected in 30% of patients with PAD and needs different therapy regimens (Fig. 1). The gold standard for treatment of long occlusions and long critical stenoses in the middle and distal sections of the SFA with insufficient profunda collaterals is the femoropopliteal bypass technique with natural or artificial artery replacement. Graft materials, stage of atherosclerosis distal of the treated section, as well as distal blood runoff are crucial for the long-term patency rates, which are in the end suboptimal with 32% to 73% after 5 years. Additionally, this treatment causes rather extensive surgical strain on the often multimorbid patients.

The alternative treatment options comprise percutaneous interventional procedures as well as combinations of percutaneous interventions and surgery. The percutaneous balloon angioplasty is a minimal invasive and rapid method with low rates of peri-interventional complications. Additional ablative procedures are available leading to partial disintegration of the plaque and its fixation in the vessel wall by stent-angioplasty. However, all interventional procedures suffer from low long-term patency rates, probably due to the thrombogenicity of the recanalized vascular lumen.<sup>4</sup>

\*Address all correspondence to: Justus Groß, E-mail: justus.gross@uksh.de



**Fig. 1** (Left side) Vascular anatomy of the pelvis and the upper leg; (right side) treatment options for critical stenoses/occlusions depending on the vascular territories; 1: open surgical approach, 2: endarterectomy, 3: bypass, 4: Moll-ring-cutter/LSD, and 5: percutaneous transluminal angioplasty (PTA).

Another alternative option—and actually the basis for our proposed device—is the Moll-ring-technique.<sup>5</sup> This device was designed to transect the distal end of the atheromatous core. It consists of stainless steel double ring cutters and a hypotube. After circular preparation of the media-adventitia-interface proximal of the occlusion, the device is inserted and propagated in the vessel wall with a high mechanical pressure. Upon activation of the proximal handle, the two distal ring cutters transect the atheroma core which can then be removed. This procedure causes significantly less surgical strain on the patients. A major disadvantage of this technique is the poor long-term patency. In systematic reviews, the average technical success rate was 94% and the weighted mean cumulative primary patency rates were 60%, 57%, and 35% at 1, 2, and 5 years, respectively.<sup>5</sup> The high mechanical stress causes substantial trauma to the vessel, and the inner vascular surface seems to be highly thrombogenic due to the significant amount of media and media-intima complex remaining in most cases which cause the poor patency. In comparison, superior patency rates can be found in literature concerning open endarterectomy for which the dissection at the media-adventitia interface is obligatory with only the adventitial layer remaining. This surgical technique allows the meticulous removal of the fibers of the media and will frequently let the vessel dilate beyond its original size, leaving a smooth vascular wall without remnant circular media fibers.<sup>6,7</sup> However, this surgical concept can be used only in the proximal femoropopliteal region, while other options are needed for distal stenoses and occlusions.

Thus, all currently available treatment options fail to provide sufficient long-term patency rates, which lead to high rates of reinterventions and eventually amputations of the limbs. Due to the high prevalence of PAD in the population, novel

techniques are urgently needed which reconstitute maximal blood supply to the lower limb rapidly and are minimally invasive, combined with higher patency rates. Ideal treatment of long occlusions of the femoropopliteal segments has not been established to date, although the role of endovascular techniques used in the treatment of SFA occlusions is increasing.<sup>4</sup>

In this proof of principle study, we propose a novel approach for laser-based remote endarterectomy, called laser scoop desobliteration (LSD). The principle of the Moll-ring-cutter, i.e., removal of the atheromatous core as a whole by remote dissection of the vascular wall, represents the basis for the construction of the LSD. The goal was to achieve dissections at the media-adventitia interface with a similar accuracy as with open endarterectomy using a minimally invasive remote access, so that chronically occluded SFA can also be subjected to revascularization. Therefore, results of the dissections using the LSD were compared with those obtained with a Moll-ring-device to investigate the respective morphologies of the atheromatous cores as rough indicators for the potential thrombogenicity of the remaining vessel walls in this proof-of-principle study, although the clinical outcomes for the Moll-ring-cutter have been disappointing. Using a laser seems to be especially promising since an increasing number of studies indicate the superior efficacy of interventional technologies performed with an excimer laser in in-stent restenosis of the femoral artery. The results of the CELLO registry (Excimer Laser Recanalization of Femoropopliteal Lesions and 1 year patency) report an intraluminal ablation of atherosclerotic plaque from  $77\% \pm 15\%$  at baseline to  $34.7\% \pm 17.8\%$  diameter stenosis in 65 patients.<sup>8</sup> Concerning the treatment of in-stent-stenosis, the EXCITE ISR Study (EXCimer Laser Randomized Controlled Study for Treatment of Femoropopliteal In-Stent Restenosis) laser recanalization and angioplasty reliably achieved superior safety and efficacy compared with PTA alone. The target lesion revascularization was 73.5% versus 51.8% ( $p < 0.005$ ), and 30-day major adverse event rates were 5.8% versus 20.5% ( $p < 0.001$ ), respectively.<sup>9</sup>

The catheter prototype was constructed and evaluated using cadavers fixed with the Thiel embalming technique allowing preservation of tissue consistency, flexibility, and plasticity. The idea is to develop a system which combines the principle method of remote endarterectomy of the Moll-ring-cutter with a laser spatula allowing a meticulous preparation close to the adventitia. We expect this technique to be less traumatic than the Moll-ring-cutter procedure due to the use of laser energy instead of mechanical plaque extraction together with a dissection, which is set precisely at the media-adventitia interface so that the atheroma core can be removed completely.

The focus of the application of the laser spatula is severely calcified and subtotal to a completely occluded SFA, where established interventional intraluminal therapies fail. After proximal dissection of the adventitia, the firm intraluminal plaque cylinder serves as a guiding axis to the rotating advance of the LSD. The calcified core can be pulled out such as in the Moll-ring procedure in the proximal popliteal arterial section, where the atherosclerotic layers thin out and form a trailing edge of the intraluminal cylinder. The application is limited to the SFA because of its anatomical accessibility via an inguinal approach. It tends to early calcification in the progression of atherosclerosis due to its anatomical location within the Hunters channel. Additionally, it usually shows a very straight pathway with only minor variations in lumen sizes, minimizing the risk of

vessel perforations. We expect that the LSD would not be successful in strongly curved or angulated vessels.

The experiments revealed that the surgery with this catheter can be performed rapidly and in a minimally invasive manner. This novel approach offers a high potential for further clinical investigation and may eventually result in improved patency rates in PAD of the SFA.


## 2 Materials and Methods

### 2.1 Construction of the Catheter Prototype


The shape of the carbon scoop was designed using the CAD software CATIA V6 (Dassault Systems, Vélizy-Villacoublay Cedex, France) (Fig. 2). The catheter prototype is based on an SLS II 16 F laser sheath (Spectranetics Inc., Colorado Springs, Colorado). The glass fibers of this catheter are manufactured using a proprietary formulation that has been optimized by Spectranetics to carry 308-nm light.

The company was informed about the changes performed, and five catheters were obtained from Spectranetics Inc. The concept comprised a spatula head design with a length of 15 cm and the glass fibers of the SLS II catheter aligned in parallel on the concave side.

For construction purposes, the tip of the catheter was opened and the rubber protective covers as well as the metal TipCap were removed to access the glass fibers. Three different construction strategies were tested, placing the fibers on the concave part: first the glass fibers were fixed with epoxy resin on a curved tinplate [Fig. 3(a)]. In a second approach, a carbon corpus and a standard vacuum injection technique were used, after preliminary fixation of the glass fibers with epoxy resin [Fig. 3(b)]. In the third strategy, a carbon fiber mat (205 g/m<sup>2</sup>) was



**Fig. 2** (a) CAD images of the scoop-shaped catheter tip; and (b) photographs of the prepared prototype.



**Fig. 3** Different strategies for the catheter construction: (a) fixation of the glass fibers (white dots) on a curved tinplate resulted in convergence of the fibers at the lowest point due to inertia; (b) usage of a carbon corpus and fixation of the glass fibers with vacuum injection technique still lead to bundling of the fibers at the vertex; and (c) usage of a carbon mat with preliminary fixation of the glass fibers and consecutive bending to the requested angle followed by lamination by vacuum injection technique resulted in entirely parallel alignment of the glass fibers.

used with a thickness of 1 mm and a fiber volume fraction of 60%. It was cut into shape and inserted into a mold filled with release agent [Fig. 3(c)]. The glass fibers of the SLS II catheter were aligned in parallel and temporarily fixed with epoxy resin. When the resin had cured, the carbon mat together with the glass fibers was cautiously bent until the favored curvature was reached. Afterward, the glass fibers were covered by a separation layer and flow agent facilitating the homogeneous flow of the laminating resin (E45KL, 10:6; Carbon-Sperling). After sealing with vacuum sealant tape, the mold was evacuated by a slide vane rotary vacuum pump until the fibers were completely impregnated with laminating resin. Surplus resin was collected in a resin trap after passing the fibers. The curing time was 200 min. The corpus was treated with wet abrasive paper and the glass fibers overhanging the edges of the carbon sleeve were cut and proprietarily polished.

The completed prototype catheter was connected to a commercially available CVX-300 Excimer Laser System (Spectranetics Inc.) operating at a wavelength of 308 nm with an energy rate of 52.4 mJ at repetition rates of 80 Hz with a fluence of 50 and a clinical energy setting of 16.6 mJ/mm<sup>2</sup>.

### 2.2 Cadaver Fixation

All experiments performed were approved by the local ethics committee of the Anatomical Institute of the University Basel, Switzerland. Conventional fixation of human cadavers by formalin-containing compounds is of limited use for surgical interventions due to the profound changes of color, induration of soft tissues, and fragility of organs. The alternative Thiel embalming technique preserves the organs and tissues concerning color, consistency, flexibility, and plasticity.<sup>10,11</sup> Embalming was performed according to Wilke et al.<sup>12</sup> This protocol is based on the use of 4-chloro-3-methylphenol, various salts for fixation, boric acid for disinfecting, and ethylene glycol, while the concentration of formalin is kept to a strict minimum (0.8%).

### 2.3 Preoperative CT Scans

CT scans of the fixed cadavers were performed preoperatively using a Siemens Emotion 16 CT scanner. The legs were scanned with a slice thickness of 0.75 cm at 130 kV and 133 mAs. Based

on these images, four corpses were chosen with similar diameters of the SFA of about 5 mm and a comparable amount and morphology of the calcifications of the vessel walls. This procedure facilitated the comparability of the results of the endarterectomies in this pilot study. After atherectomy, the arteries were removed and scanned with a slice thickness of 0.6 mm at 130 kV and 200 mAs.

## 2.4 Surgical Procedure

All experiments were conducted at room temperature without heating the corpses to body temperature. Surgery was performed in a standardized manner on the four corpses chosen by preoperative CT scans as described above. Both legs of each cadaver were used, so that the LSD maneuvers and the Moll-ring maneuvers could be conducted on four SFAs each. Since the vascular punctures for fixation of the corpses had been performed rather caudally, the adductor canals were opened for access to the SFA. A longitudinal arteriotomy was performed in the proximal sections directly below the vascular punctures, followed by a circular endarterectomy at the media–adventitia interface using a dissector. The calcified intima-media complexes were left *in situ*. In the LSD group, the catheter prototype was inserted dorsally of the atheroma cores and propagated over a distance of 15 cm rotating at 360 deg. An output energy of 16.6 mJ/mm<sup>2</sup> at a repetition rate of 80 Hz was chosen. Propagation was performed manually but the microchronometer was controlled with a progress of 1 mm/s. Then the atheroma core was removed. The Moll-ring procedure was performed accordingly.

All recanalizations were performed by the same examiner. The force used to duct the LSD and the Moll-ring device through the media–adventitia interface was always as low as was reasonably achievable.

## 2.5 Histological Preparation

The treated vessels of both groups were resected and preserved in 10% formalin for 24 h for further investigation. The formalin-fixed desobliterated vessels were then embedded in paraffin using standard procedures.

Paraffin sections with a thickness of 4 μm were deparaffinized in xylene and rehydrated in a descending alcohol series. H&E staining was performed according to standard protocols for general morphology of the remaining vessel wall components after surgery. A routine protocol for Verhoeff's Van Gieson staining was used to visualize elastic fibers in order to identify the external elastic lamina and the adventitia.

The accuracy of the endarterectomy at the media–adventitia interface as well as the amount of remaining media fibers were evaluated on the basis of this histological staining as a primary endpoint of this proof-of-principle study. Evaluation of possible penetrations as well as thermal damage served as secondary endpoints.

## 3 Results

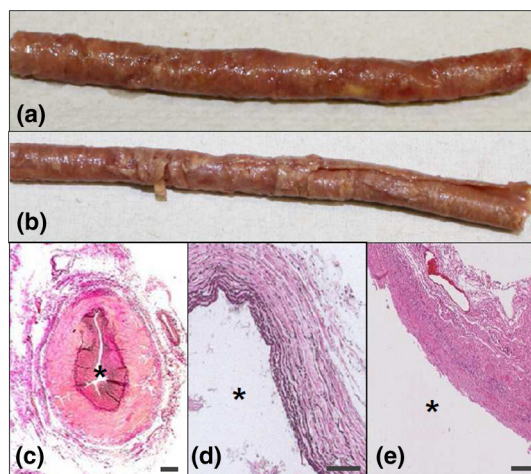The LSD catheter design comprises a 15-cm long spatula head with the glass fibers of the SLS II catheter aligned in parallel on the concave side. Since approximately 128 fibers are used in the construction of an SLS II catheter, each of 100-μm diameter, this equals a spot size/ablation area of 1 mm<sup>2</sup>. Three construction strategies were used and evaluated as follows using five catheters in total: fixation of the glass fibers on a curved tinplate with epoxy resin led to convergence of the fibers at the lowest point

due to inertia [Fig. 3(a)]. Usage of a carbon corpus with a vacuum injection technique improved the results; however, bundling of the fibers at the vertex could not be prevented [Fig. 3(b)]. Only the use of a carbon mat with preliminary fixation of the glass fibers and consecutive bending to the requested angle followed by lamination by a vacuum injection technique resulted in the entirely parallel alignment of the fibers [Fig. 3(c)]. The pilot experiments on the cadavers were performed with one prototype catheter manufactured according to this last strategy (LSD catheter), since the scope of the current study was to test the feasibility of the LSD approach in the SFA.

Despite parallel alignment of the fibers, the first testing of the prototype revealed a significant energy loss at the tip of the LSD catheter. The difference of the energy input (52.4 mJ/mm<sup>2</sup>) and the energy output (16.6 mJ/mm<sup>2</sup>) accounted for 35.8 mJ/mm<sup>2</sup>. This was probably due to imperfect proprietary polishing of the fiber ends and should be improved before further experiments are performed. However, the output energy was sufficient for pilot tests in the sense of a proof-of-principle study.

In terms of standardization and comparability, we selected four cadavers with comparative SFA diameters of about 5 mm and similar morphologies based on the preoperative CT scans as described. Both legs of each cadaver were used, thus eight SFAs could be treated with either the LSD catheter or the Moll-ring device. Each of the eight treated arteries showed circular calcification of at least the proximal 15 cm.

Insertion of the LSD catheter prototype and of the Moll-ring cutter as well as extraction of the atheroma cores were, in general, easy and rapid to perform. However, a rather steep angle was needed to insert the LSD catheter prototype into the chosen vascular wall layer while the Moll-ring device needed a comparatively higher mechanical pressure to be pushed forward. No penetration of the outer vascular surface was seen in both groups. Macroscopic inspection of the inner vascular surface revealed no thermal damage. Histological examination showed an intact adventitial layer in both groups, accordingly. The surface of the extracted intima-media complex in the LSD group displayed a principally straight and regular shape without attaching tissue debris [Fig. 4(a)]. The atheroma cores in



**Fig. 4** (a) Photograph of the calcified intima-media complex extracted by LSD; (b) photograph of the calcified intima-media complex extracted by Moll-ring-cutter; (c)–(e) histological aspects of the vessel wall treatment with staining of the elastic fibers (c) before treatment, (d) after treatment with the LSD, and (e) after treatment with the Moll-ring-cutter (scale bar: 100 μm; \*: lumen).

the Moll-ring group, however, showed a rather irregular surface with numerous cuts and remaining tissue layers [Fig. 4(b)]. Histological analysis confirmed this difference, since the removal of almost all media materials was observed in the histological samples of the LSD group [Figs. 4(c)–4(e)], while remaining media fibers were detected in the histological samples of the Moll-ring group.

## 4 Discussion

Stenosis and occlusion of the SFA are most common in PAD.<sup>13</sup> The main factor for restenosis of a recanalized vessel is the degree of thrombogenicity of the remaining vessel wall.<sup>14–16</sup> Thus, open endarterectomies with the exact selection of a defined vascular wall layer and complete removal of the atheromatous core show patency rates of >90% in 5 years. However, endarterectomy is not performed in long-segment stenoses/occlusions in the middle and distal sections of the SFA due to very high reocclusion rates. Long-term patency rates of alternative interventional, surgical, and combined approaches are better compared with endarterectomy, but are still not satisfying.

In the present study, a novel catheter for laser-based semiclosed endarterectomy was constructed for atraumatic long-segment recanalization of the SFA. A 15-cm long spatula with an oval tip was chosen as a design principle that facilitates smooth propagation of the catheter in the selected vascular wall layer. The glass fibers of the SLS II 16 F laser catheter should be aligned in parallel on the concave side of the spatula. Different construction strategies were tested and bundling of the fibers at the vertex appeared to be the biggest obstacle. This could be prevented by fixing the glass fibers first by epoxy resin to a plane carbon mat and consecutive bending to the requested angle after the resin had cured.

However, the energy loss of 68% in the catheter was very high. Light exiting the fibers can cause damage to the fibers if the final polish is imperfect. Since only proprietary polishing was available, the loss of power transmission experienced in this early prototype was probably due to the fact that the fiber tips were not polished to the same standard as in finished SLS II catheters. A further optimized design of the fiber tips may also lead to a more effective power performance. This needs to be improved for clinical studies. Additionally, before a clinical trial is initiated, additional data are required for reproducibility of the catheter production and the limit for possible variations needs to be defined according to applicable law.

Nevertheless, the pilot experiments with Thiel-embalmed corpses showed encouraging results. In general, the torsional stiffness of the corpses was sufficient to rotate the LSD catheter for 360 deg even when it was fully inserted, and application of the Moll-ring device was also feasible. The LSD approach as well as the Moll-ring approach both could rapidly be performed without any penetration of the outer vascular wall as determined by macroscopic inspection. This is facilitated by usually only limited variations in vessel diameters of the SFA and by the generally straight pathway of the SFA that is obtained even in patients with arterial hypertension.

Both procedures are preceded by open surgical cut-down and preparation of the bifurcation of the common femoral artery proximal to the occlusion. This open approach facilitates exact selection of the vascular wall layer where the dissection is performed, and a well-defined extraction of vascular plaques. This is essential for a long-segment endarterectomy with the

lowest thrombogenicity of the remaining vascular wall due to complete removal of the intima-media complex.<sup>6,7</sup> The interventional character of the dissection procedure as such, even over longer vascular sections, may lead to a comparably low strain for this often multimorbid patient population hopefully resulting in short hospitalizations.

The atraumatic propagation of the LSD catheter is enabled by a laser system operating at a wavelength of 308 nm and is mainly based on heating and vaporizing of the intracellular water by photothermal effects.<sup>17</sup> Together with photomechanical interactions, this leads to the fracture of molecules and cellular fragmentation. Associated with the manual control of catheter propagation, the LSD provides a highly defined and atraumatic semiclosed vessel plaque extraction of the SFA. Since the preparation level between adventitia and media layers is virtually anatomically preformed, only a small amount of energy is needed for sufficient preparation. No thermal damage of the adventitia could be observed after application of the laser at room temperature. To exclude the potential of thermal damage completely prior to a clinical study, these experiments may be repeated at a 37°C tissue temperature to mimic the clinical conditions better. The extracted atheromatous core showed a straight and plane surface, and histological examination confirmed extraction of almost all media materials.

In contrast, the Moll-ring cutter has to be pushed forward with comparatively high mechanical force. This resulted in a more irregular shape of the removed intima-media complex with several cuts and attached tissue flaps. Additionally, remaining thrombogenic material could be detected inside the artery. Therefore, the laser technique seems to be less traumatic and more exact, and the reduction of thrombogenic material at the inner vessel surface using the LSD catheter prototype may eventually result in improved patency rates.

Some further adjustments can improve the handling of the LSD catheter. The radius of the device of 0.5 cm should be decreased for further experiments to fit the diameter of the SFA better. Additionally, the preparation angle that was needed to insert the device into the chosen vessel wall layer was rather steep. This significantly enhanced the risk of tangential damage of the adventitial layer. Thus, the flexibility of the device needs to be increased. The prototype allowed operation only with a single energy output (16.6 mJ/mm<sup>2</sup>) and a single repetition rate (35 Hz). Thus, no prediction is possible how about different energy output parameters and repetition rates will influence the results of the LSD. This should be tested prior to clinical studies. Additionally, experiments should be performed to discriminate the dissection results in vessels with critical stenoses versus chronically occluded vessels.

For the treatment of in-stent restenoses in the femoral artery, promising results were obtained using an excimer laser,<sup>8,9</sup> and Spectranetics recently obtained FDA approval in the United States for this indication. The difference of the excimer laser approach and the LSD concerns the strategy to extract the atheromatous core: while the excimer laser removes the occluding material from the lumen toward the stent, the LSD performs a dissection at the media–adventitia interface for removal of the core as a whole. Therefore, both methods complement each other since the excimer laser seems to have advantages in the case of in-stent restenoses while the LSD seems to be more suitable for treatment of chronically occluded SFA. This was the rationale to use the chosen Excimer Laser System for construction of the LSD.

Clinical studies are also needed to compare LSD with standard therapy regimens. However, patient selection for these studies should be conducted considerably. The pathogenesis of atherosclerotic plaque formation as well as the micromorphology of the plaques such as the amount of necrotic plaque core, the amount of calcifications, and the plaque relief should especially be taken into account. The heterogeneity of concomitant diseases in patients suffering from PAD complicates the exact correlation of pathogenesis and plaque characteristics. However, morphological aspects obtained by diagnostic imaging should be taken into account. For this proof-of-principle study, only a limited number of cadavers were available for the surgical procedures. To facilitate comparability of the results, we concentrated on plaques that were highly calcified over at least 15 cm since these plaques were easy to detect on the preoperative CT scans. When a clinical trial is designed, ultrasound as well as CT morphology should be considered for preoperative characterization of the plaques as well as thorough histological analysis of the resected atheromatous core to determine the micromorphology of the removed plaques. This will be important for understanding correlations between plaque morphology and patency rates. Patients with infections or preceding surgery of the lower limbs or the groin should be excluded at least from the early studies to minimize confounding factors. A prospective design of a clinical study should additionally consider clinical criteria like age, social risk factors for PAD, hyperlipoproteinaemia, diabetes mellitus, as well as the general condition of the patients.

In summary, the proof-of-principle study with Thiel-fixed cadavers shows that endarterectomy at the media–adventitia interface is feasible with the early LSD catheter prototype in general. Some improvements in the design of the prototype are needed as well as more data on the reproducibility according to clinical and morphologic aspects of atherosclerotic plaque, as described, before starting clinical studies. However, the results of the presented proof-of-principle study are encouraging, indicating that LSD can offer a significant impact on the treatment of SFA occlusions in PAD.

### Acknowledgments

We would like to thank Spectranetics Inc., Colorado Springs, Colorado, USA, for providing the SLS II catheters for this trial. Furthermore, we thank Fred Peter for his technical support. Also, we like to thank all the members of the Institute of Anatomy of the University of Basel, Switzerland, for their instant and immediate support.

### References

1. C. Diehm, S. Kareem, and H. Lawall, "Epidemiology of peripheral arterial disease," *Vasa* **33**(4), 183–189 (2004).
2. Q. T. Bui, M. Prempeh, and R. L. Wilensky, "Atherosclerotic plaque development," *Int. J. Biochem. Cell Biol.* **41**(11), 2109–2113 (2009).
3. S. S. Gisbertz et al., "Short-term results of a randomized trial comparing remote endarterectomy and supragenicular bypass surgery for long occlusions of the superficial femoral artery [the REVAS trial]," *Eur. J. Vasc. Endovasc. Surg.* **37**(1), 68–76 (2009).
4. J. Fialova et al., "Current treatment methods for long occlusions of the femoropopliteal segment in patients with intermittent claudication. Minireview," Biomedical papers of the Medical Faculty of the University Palacky, Olomouc, Czechoslovakia (2013).
5. G. A. Antoniou et al., "Remote endarterectomy for long segment superficial femoral artery occlusive disease. A systematic review," *Eur. J. Vasc. Endovasc. Surg.* **36**(3), 310–318 (2008).
6. T. Inahara, "Endarterectomy for occlusive disease of the aortoiliac and common femoral arteries. Evaluation of results of the eversion technic endarterectomy," *Am. J. Surg.* **124**(2), 235–243 (1972).
7. D. Mukherjee, W. J. Schickler, and T. Inahara, "The superficial femoral artery as a conduit: an alternative to prosthetic material," *J. Vasc. Surg.* **2**(5), 739–740 (1985).
8. R. M. Dave et al., "Excimer laser recanalization of femoropopliteal lesions and 1-year patency: results of the CELLO registry," *J. Endovasc. Ther.* **16**, 6656–6675 (2009).
9. E. J. Dippel et al., "Randomized Controlled Study of Excimer Laser Atherectomy for Treatment of Femoropopliteal In-Stent Restenosis: Initial Results From the EXCITE ISR Trial (EXCimer Laser Randomized Controlled Study for Treatment of Femoropopliteal In-Stent Restenosis)," *JACC Cardiovasc Interv.* **8**, 92–102 (2015).
10. K. D. Wolff et al., "Thiel embalming technique: a valuable method for microvascular exercise and teaching of flap raising," *Microsurgery* **28**(4), 273–278 (2008).
11. R. Eisma, C. Lamb, and R. W. Soames, "From formalin to Thiel embalming: what changes? One anatomy department's experiences," *Clin. Anat.* **26**(5), 564–571 (2013).
12. H. J. Wilke et al., "Thiel-fixation preserves the non-linear load-deformation characteristic of spinal motion segments, but increases their flexibility," *J. Mech. Behav. Biomed. Mater.* **4**(8), 2133–2137 (2011).
13. S. Tamar et al., "High-risk plaque in the superficial femoral artery of people with peripheral artery disease: prevalence and associated clinical characteristics," *Atherosclerosis* **237**(1), 169–176 (2014).
14. K. Yahagi et al., "Pathophysiology of superficial femoral artery in-stent restenosis," *J. Cardiovasc. Surg. (Torino)* **55**(3), 307–323 (2014).
15. M. Bartel et al., "[Results later many years after TEA in femoro-popliteal segment (author's transl)]," *Z. Alternsforsch.* **33**(5), 401–407 (1978).
16. E. S. Debus et al., "Regionale Erkrankungen der Arterien: Femoropoplitealer Gefäßabschnitt," in *Operative und interventionelle Gefäßmedizin*, E. S. Debus and W. Gross-Fengels, Eds., pp. 99–110, Springer, Berlin, Heidelberg (2012).
17. B. L. Wilkoff et al., "Pacemaker lead extraction with the laser sheath: results of the pacing lead extraction with the excimer sheath (PLEXES) trial," *J. Am. Coll. Cardiol.* **33**(6), 1671–1676 (1999).

Biographies of the authors are not available.