

# Light-guided lumpectomy: device and case report

## Amanda Dayton

Providence St. Vincent Medical Center  
Oregon Medical Laser Center  
9555 SW Barnes Road  
Portland, Oregon 97225  
and  
Oregon Health & Science University  
Department of Biomedical Engineering  
3303 SW Bond Avenue  
Portland, Oregon 97239

## Laurel Soot

Providence St. Vincent Medical Center  
Ruth J. Spear Breast Center  
9205 SW Barnes Road  
Portland, Oregon 97225  
and  
The Oregon Clinic  
Westside Surgical Division  
9155 SW Barnes Road  
Portland, Oregon 97225

## Ronald Wolf

The Oregon Clinic  
Westside Surgical Division  
9155 SW Barnes Road  
Portland, Oregon 97225

## Christina Gougoutas-Fox

Providence St. Vincent Medical Center  
Ruth J. Spear Breast Center  
9205 SW Barnes Road  
Portland, Oregon 97225

## Scott Prah

Providence St. Vincent Medical Center  
Oregon Medical Laser Center  
9555 SW Barnes Road  
Portland, Oregon 97225  
and  
Oregon Health & Science University  
Department of Biomedical Engineering  
3303 SW Bond Avenue  
Portland, Oregon 97239

## 1 Introduction

For small breast cancers and precancerous conditions a lumpectomy, also called breast-conserving surgery, is often performed. In this surgical technique, the lesion and surrounding tissue are removed but the remainder of the breast is left intact. More than 340,000 lumpectomies were performed<sup>1,2</sup> in 2006 in the United States and this number has increased steadily over the last decade.<sup>3-7</sup> In this paper, we describe the development of a device to assist surgeons in removing small nonpalpable breast lesions found.

**Abstract.** We describe the development, design, fabrication, and testing of an optical wire to assist in the surgical removal of small lesions during breast-conserving surgery. We modify a standard localization wire by adding a 200- $\mu\text{m}$  optical fiber alongside it; the resulting optical wire fit through an 18 gauge needle for insertion in the breast. The optical wire is anchored in the lesion by a radiologist under ultrasonic and mammographic guidance. At surgery, the tip is illuminated with an eye-safe, red, HeNe laser, and the resulting glowball of light in the breast tissue surrounds the lesion. The surgeon readily visualizes the glowball in the operating room. This glowball provides sufficient feedback to the surgeon that it is used (1) to find the lesion and (2) as a guide during resection. Light-guided lumpectomy is a simple enhancement to traditional wire localization that could improve the current standard of care for surgical treatment of small, nonpalpable breast lesions. © 2010 Society of Photo-Optical Instrumentation Engineers. [DOI: 10.1117/1.3499422]


Keywords: biomedical optics; lasers in medicine; optical devices; breast cancer; optical wire; lumpectomy; breast-conserving surgery.

Paper 10096SSR received Feb. 24, 2010; revised manuscript received Jun. 22, 2010; accepted for publication Aug. 9, 2010; published online Nov. 10, 2010.

In 1980, Kopans and DeLuca introduced the hookwire technique to improve the preoperative localization of breast lesions.<sup>8</sup> The hookwire is a 20- to 25-cm-long thin wire bent at the tip to form a V-shaped hook and is now referred to as the Kopans wire. In practice, a radiologist places a needle in a lesion using either x-ray or ultrasound guidance then slides the Kopans wire, hook end first, through the needle. Once the needle is removed, the hook springs open and is anchored at the lesion site. The wire external to the skin is taped in place to prevent its displacement. Proper localization is confirmed with orthogonal mammograms and the patient is sent to the operating room.

---

Address all correspondence to: Scott A. Prah, Providence St. Vincent Medical Center, Oregon Medical Laser Center, 9205 SW Barnes Rd., Portland, OR 97225. Tel: 503-216-2197; Fax: 503-216-2422; E-mail: prahl@bme.ogi.edu.



**Fig. 1** Optical wire used for light-guided lumpectomy. The device consists of a 200- $\mu\text{m}$  optical fiber adhered to a standard Kopans wire.

The surgery is guided by the anchored Kopans wire. The surgeon views the mammograms and observes the general location of the lesion and wire. Since the end of the wire is in the lesion, the surgeon uses the wire to find the small nonpalpable lesion. The surgeon will try to remove the lesion with disease-free surrounding tissue; consequently, before reaching the end of the wire, the surgeon must deviate from the wire and then reapproach it to excise the tissue surrounding its tip. The exact point to deviate from and approach the wire is unclear and can cause the resection to be scalloped (i.e., the cut was either too close or too far from the lesion and the distance required correction). At a minimum, if diseased tissue is found within 2 mm of the surface of the resected tissue, the margin is positive and a second surgery is indicated. Scalloped borders are irregular and can result in positive margins.

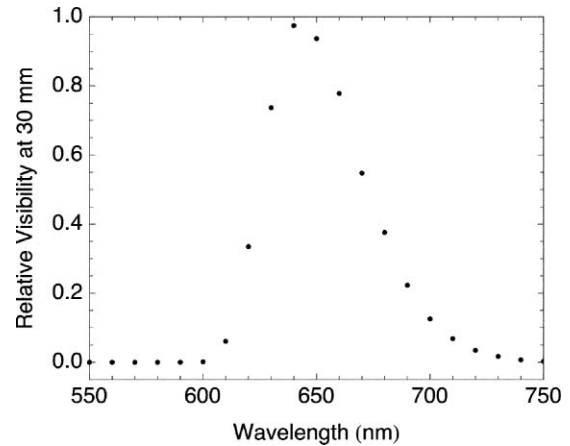
The radiologist places the wire parallel to the chest wall because it is the safest and most accurate method of localization.<sup>9</sup> However, this approach is not necessarily ideal for the surgeon. Often, to avoid following the wire from the skin to the lesion, surgeons will anticipate the location of the tip to properly place the skin incision. After this incision is made, the wire is cut near the skin, pulled into the incision and followed to the lesion. Despite the wire guidance, these procedures are often repeated due to positive margins. The rates of published<sup>10–16</sup> positive margins range from 10 to 50%.

We hypothesized that the standard wire-guided lumpectomy could be improved by using light. The standard Kopans wire would be replaced by an optical wire that illuminated the breast and produced a glowball of light that surrounded the lesion. This glowball might assist surgeons in both locating and resecting nonpalpable lesions by providing a visible, spherical target. The optical wire would be placed by a radiologist using the same technologies as are currently used for Kopans wires. To maintain the current standard of care, the optical wire consisted of a Kopans wire attached to a 200- $\mu\text{m}$  optical fiber with medical grade epoxy, as shown in Fig. 1. This paper is a description of the device and a case report on its use.

## 2 Benchtop Development

### 2.1 Visibility

One primary goal of light-guided lumpectomy was to ensure visibility of the glowball during surgery with no necessity for eye protection or imaging devices. To maximize light penetration through tissue, the illumination would ideally be at an IR wavelength such as 800 nm. In fact, this wavelength works well when semiconductor-based sensors are used to detect light, but is well outside the range of sensitivity of the human eye (400 to 700 nm). The 800-nm wavelength can be seen using IR night



**Fig. 2** Simulated relative visibility of light through 30 mm of breast tissue shows a peak near 650 nm. The overall visibility was normalized to 1.

vision goggles, but this is impractical in the operating room. Instead, one must find a wavelength that maximizes light penetration (longer wavelengths) and also maximizes visibility (shorter wavelengths). The visibility of light transmission through breast tissue might be estimated as the product of the light transmitted through 10 mm of breast tissue and the sensitivity of the human eye. Both normal and diseased breast tissue<sup>17–23</sup> have reduced scattering coefficients ( $\mu'_s$ ) that range from 0.5 to 2.0  $\text{mm}^{-1}$ . The absorption coefficient ( $\mu_a$ ) of breast tissue in the visible range of the spectrum is dominated by hemoglobin.

The spectral behavior of scattering was assumed to be

$$\mu'_s = 0.4 \left( \frac{\lambda}{650 \text{ nm}} \right)^{-0.7} \text{ mm}^{-1},$$

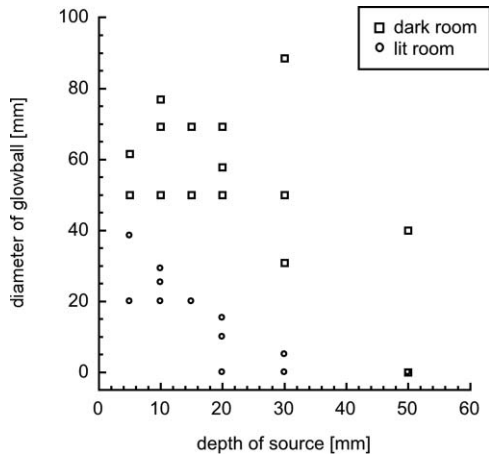
where  $\lambda$  is the wavelength; this was based on van Veen et al.<sup>23</sup> from intraoperative optical properties of normal breast tissue. The absorption coefficient ( $\mu_a$ ) was determined by a nominal hemoglobin concentration of 2% with 80% oxygenation. A point source diffusion model,<sup>24</sup>

$$\frac{3(\mu_a + \mu_s)}{4\pi r} \exp[-r\sqrt{3\mu_a(\mu_a + \mu'_s)}],$$

was used to determine the fraction of light emitted by the optical fiber that passed through  $r = 30$  mm of simulated breast tissue. This fraction was then multiplied by the CIE 1951 standards of luminous efficiency for the (light adapted) photopic eye<sup>25</sup> to obtain an estimate of relative visibility as a function of wavelength (Fig. 2). In this graph, the dramatic increase in visibility at 600 nm is caused by a decrease in light absorption by blood. The decrease in visibility approaching 700 nm is due to the sensitivity of the human eye. The optimal wavelength was conveniently around 633 nm and a red HeNe laser could be used. The scotopic (dark adapted) response (not shown) is shifted slightly to the left of the photopic curve.

### 2.2 Prophylactic Mastectomy Specimens

Based on the estimated visibility and the work of Hussman et al.,<sup>26</sup> where 635-nm light was visible through several centimeters of breast tissue, a preclinical study was established under Providence Health & Services IRB protocol 06-29B. Three subjects undergoing prophylactic mastectomy were



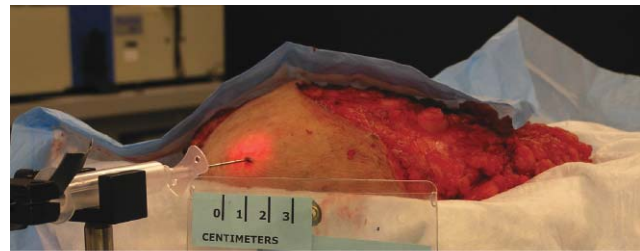
**Fig. 3** Diameter of visible light through mastectomy tissue as the depth of a 3-mW 633-nm light source was increased. Visible diameter is shown under typical laboratory lighting (lit) conditions and with most laboratory lights off (dark).

informed, consented to, and enrolled in the study. Immediately after the surgery was completed, but before pathological evaluation, the cancer-free mastectomy specimen was brought to the lab for evaluation. Green (543-nm, 8-mW HeNe laser), red (633-nm, 15-mW HeNe laser), and white (Oriol tungsten lamp) light was stereotactically delivered within the tissue through an 800- $\mu\text{m}$  optical fiber. Approximately 3-mW of light was emitted from the fiber for each light source. Visibility was evaluated at 5-mm intervals from 5 to 60 mm under bright (300 lx) and dim (2 lx) room lighting conditions. The diameter of the light centered around the source fiber and emitting from the tissue was measured for each source, depth, and room lighting condition with a ruler and the eye as a detector. The green light was visible only under dim room lights at 5 mm and under no other conditions. In a dim room, the red and white light had a 50-mm-diam depth at source depths of 5 to 30 mm; the light could be seen at a depth of 50 but not at 60 mm. In a bright room, the red and white light had a 20-mm diameter at source depths of 5 to 10 mm; the visible diameter was reduced at longer depths and could be seen at 30-mm depth but not at any deeper locations (Fig. 3). The white light appeared red after traveling through 10 mm of tissue. Viewing the light through skin reduced the visibility distance by about half that of when skin was not present. The intensity gradient toward the source was easily visualized (Fig. 4).


### 3 Fabrication and Testing

Based on these promising *ex vivo* results we designed and built an optical wire for use during surgery. Ideally, the procedure used by the radiologist for placing the optical wire would be identical to that used for a Kopans wire; unfortunately, the added bulk of the optical fiber required that the needle size be increased from 21 to 18 gauge. This was the only change from the standard procedure used by the radiologist for placing the wire.

The diameter of the Kopans wire was 250  $\mu\text{m}$  and the diameter of the optical wire was 457  $\mu\text{m}$  (Fig. 1). The optical fiber had to be displaced from the tip of the Kopans wire by 3 mm for the assembly to pass through the 18 gauge needle. The entire length of the optical wire had to fit through the needle, which



(a)



(b)

**Fig. 4** Example of breast tissue illumination with a red laser with an optical fiber located 10 mm within the tissue. The glowball of light can be seen surrounding the needle directly above the ruler. Visualized through the skin with room lights on (a) the glowball is 2 cm in diameter and 4 cm in diameter with the lights dimmed (b).

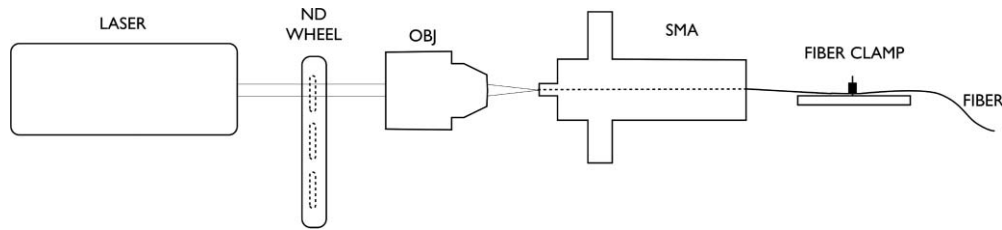
meant that the end of the optical fiber was bare and could have no connectors to facilitate light coupling. To be able to position the laser away from the sterile field in the operating room, a 3-m length of optical fiber was chosen.

#### 3.1 Light Delivery

For the glowball to be visible during lumpectomy, laser light was required to be reproducibly coupled into a bare fiber without the ability to measure the light output through the fiber. To accomplish this, the laser system was designed to be aligned with a separate 20-cm standard optical fiber. In addition, the intensity of the light emitting from the fiber was controlled so the glowball could be made smaller or larger. An adjustable neutral density filter set was used to accomplish this control with a HeNe laser.

The laser light was focused by a 10 $\times$  objective [0.3 numerical aperture (NA)]. The focal spot was located at a 200- $\mu\text{m}$  SMA (subminiature version A) connector through which the optical fiber could slide (see Fig. 5). To position the fiber, it was pushed through the SMA connector toward the objective then pushed back into the SMA connector with a 2-mm-diam rod so that the fiber face was in plane with the front of the SMA connector. To prevent the fiber from moving, a fiber holder was used to secure the fiber in place.

The system was aligned with a 20-cm-long segment of the same fiber used in the optical wire. At the free end of this standard fiber, a silicon optical sensor (Coherent, OP-2VIS) and power meter (Coherent, FieldMax II-TO) were used to measure the output. The SMA connector was translated in the plane perpendicular to the axis of the fiber until the light output was maximized. The standard fiber, aligned and then re-placed in the SMA five times, coupled  $4.4 \pm 0.6$  mW. After the standard fiber was aligned, the system was not changed except for removal



**Fig. 5** To couple light into a bare 200- $\mu\text{m}$  fiber in the operating room, the light from a 633-nm HeNe laser traveled through a neutral density filter wheel and was then focused with an objective onto the fiber face. The fiber was positioned within a fixed SMA connector and held in place with a fiber clamp. The neutral density wheel was used to control the power emitted from the fiber.

of the standard fiber and placement of the optical wire fiber. We characterized 3 m of optical fiber before attaching it to the Kopans wire. The 3-m optical wire fiber coupled  $2.7 \pm 0.4$  mW over five different placements. Due to the small standard deviation of the power output, it was assumed that the system could be aligned in the operating room using the standard optical fiber and then replaced by the optical wire fiber to achieve the power output already given.

### 3.2 Optical Wire Assembly

After the fiber was characterized, the optical wire was assembled (Fig. 6). The proximal 247 mm of a Kopans wire (Cook Medical, DKBL-25-9.0) and the distal 247 mm of the characterized optical fiber (CeramOptec, Optran WF 200/220 P) were placed within a 457- $\mu\text{m}$ -inner-diam Teflon tube so that the fiber tip was 3 mm from the bent end of the Kopans wire. Using a 30 gauge blunt-tip needle, the medical grade epoxy (LOCTITE 3921) was slowly dispensed into the Teflon tube. To cure the epoxy once the tube was filled, a UV light source (Dymax Light Welder, 3010EC) irradiated every 4 cm of the assembly for 2 min. The Teflon tube was slowly slid off of the optical wire, leaving the Kopans wire attached to the optical fiber.

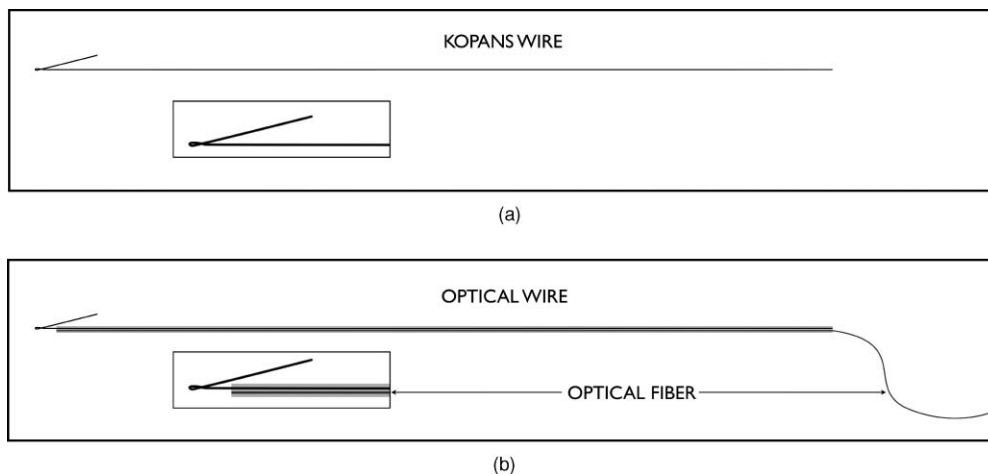
The tip of the fiber was 3 mm from the tip of the Kopans wire. The epoxy was solid and uniformly distributed over its 247-mm length. The device was packaged and sterilized by hydrogen peroxide (STERRAD).

## 4 Clinical Use

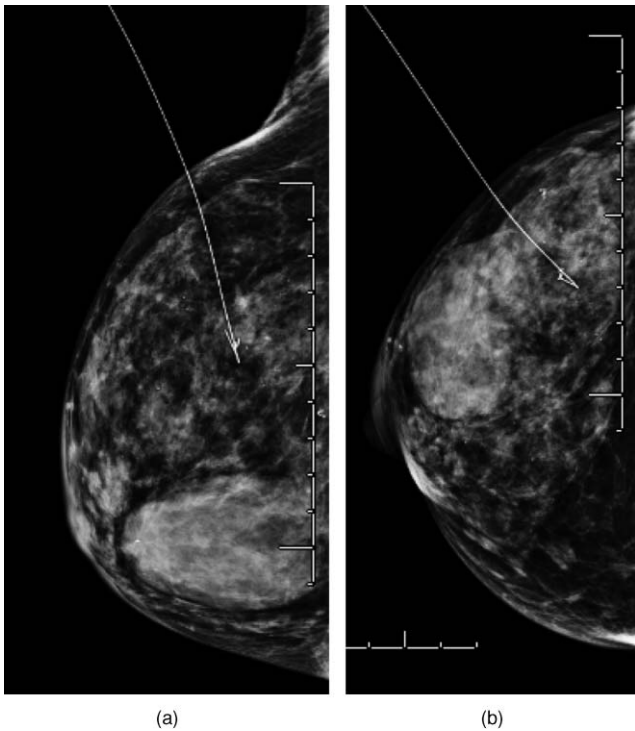
A 65-year-old female consented to and was enrolled in a phase I clinical trial of light-guided lumpectomy under Providence Health & Services IRB protocol 07-11A. Prior to enrollment, a biopsy of the lesion had proven positive for high-grade ductal carcinoma *in situ* and a radio-opaque clip was inserted at the site of the biopsy. Using sterile technique and local lidocaine, the radiologist used an 18 gauge needle to place the optical wire 40 mm into the upper outer aspect of the right breast next to the clip using ultrasound. With the tip of the optical wire anchored within millimeters of the clip, the needle was removed from the breast and the optical fiber was wound, placed between gauze and taped to the subject's skin. The localization of the lesion was confirmed with two orthogonal x-ray mammograms (Fig. 7).

The subject was taken to the operating room where she received general anesthetic and was endotracheally intubated. The laser system was aligned using the standard fiber. The optical wire fiber was untaped from the subjects skin and uncoiled. The free end of the optical wire fiber was coupled to the laser assembly and the rest of the fiber was secured with tape to prevent it from moving.

In the operating suite, the optical wire was illuminated (1 to 4 mW of power were coupled into the fiber during the procedure) and an incision was made in the upper outer quadrant where the surgeon knew the lesion was located. The room lights were turned down until the glowball was visualized by the

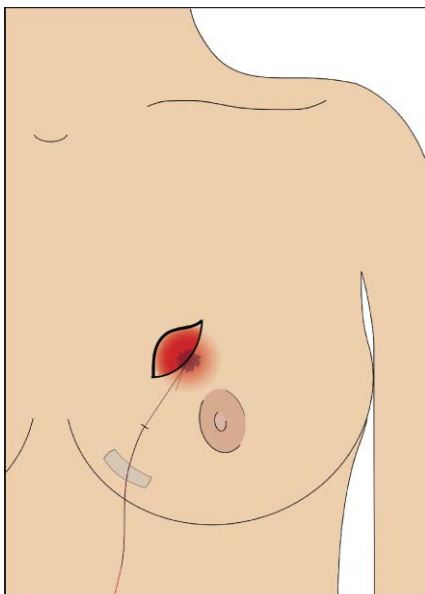


**Fig. 6** (a) Kopans wire, the standard wire used in wire-guided lumpectomies, is a thin stainless steel wire bent at its tip to anchor it in tissue once deployed. (b) assembled optical wire was composed of a Kopans wire with an optical fiber adhered to it with medical grade epoxy (light gray) along the length of the Kopans wire. The epoxy and optical fiber were offset 3 mm from the tip of the Kopans wire.



**Fig. 7** Orthogonal mammograms of the optical wire placement: (a) lateral medial projection, and (b) cranial caudal projection. The hook end of the wire and the fiber tip are within 3 mm of the biopsy clip within the lesion. Each line on the rules is separated by 1 cm.

investigators (no secondary detectors were used; Fig. 8). Using the glowball to indicate direction, the surgeon made sharp dissection superior, medial, and lateral following the light gradient. The direction of the optical wire tip was readily determined by gentle palpation of the surrounding tissue. By switching the neutral density filters, the intensity and therefore the size of the



**Fig. 8** After illuminating the optical wire, the lesion was surrounded with light that could be seen after an incision was made.

glowball was gradually reduced, as determined by the surgeon. The surgeon then began dissecting around the glowball to resect the lesion. After the specimen was completely excised, the wire was cut and the specimen sides were inked with different colors to indicate orientation. The specimen was sent for orthogonal radiographs in which the clip and wire were centrally located in the specimen so the incision was closed. The subject tolerated the procedure well with no known complications.

This procedure demonstrated the feasibility of light guided lumpectomies. The specimen was  $25 \times 56 \times 35$  mm in the anterior-posterior  $\times$  medial-lateral  $\times$  superior-inferior aspects. The subject had histologically negative margins ( $>10$  mm) and the surgeon found the glowball helpful in both localizing the nonpalpable lesion as well as resecting a relatively spherical specimen of an appropriate size.

## 5 Conclusion

Light-guided lumpectomy may enable new approaches during surgery that may lead to improved cosmetic results for the subject. Currently, surgeons must “follow the wire” either from its skin entry site (selected by the radiologist) or from a nearby incision. A circumareolar incision often has enhanced cosmetic results, but finding the tip of a traditional Kopans wire when using such an approach can be challenging.

Light-guided lumpectomy may provide simple, practical benefits to the current practice of breast-conserving surgery. On this subject, the optical wire seemed to help the surgeon find and resect a nonpalpable breast lesion. The tip of the optical wire was known to be within the lesion as it was placed with imaging guidance so that it localized a biopsy proven ductal carcinoma *in situ*. Given the known location and approximate size of the lesion from previous imaging, the surgeon was able to identify the area of breast tissue to remove. The glowball provided immediate visualization at the end of the optical wire, which the surgeon used to estimate proximity to the wire tip. As a confirmation that the lesion appeared to be contained in the lumpectomy specimen, orthogonal radiographs were taken of the specimen to provide immediate feedback to the surgeon before the incision was closed. Pathologic analysis provided final confirmation of the margin status.

Although encouraging, this is a case report and to improve clinical outcomes, the light-guided lumpectomy must demonstrate improved margin status following resection of small lesions. If successful in improving clinical outcomes, the slightly larger needle used for localization and the dimmed lights in the operating room should prove to be small adjustments to the procedure. If the optical wire can reduce the number of procedures that result in positive margins, and therefore reduce the number of repeated lumpectomies, it may not only improve patient outcomes but reduce the cost of treating breast cancer. However, this remains an open question that is being addressed in a prospective, randomized, controlled trial.

## Acknowledgment

The authors would like to recognize the Safeway Foundation for financial support and to thank Katrina Murphy for her illustrations.

## References

1. K. A. Cullen, M. J. Hall, and A. Golosinskiy, "Ambulatory surgery in the United States, 2006," National Health Statistics Reports 11, Division of Health Care Statistics, U.S. Department of Health and Human Services, Centers for Disease Control and Prevention, National Center for Health Statistics (2009).
2. "HCUP clinical classifications software (CCS) for ICD-9-CM. Healthcare Cost and Utilization Project (HCUP) 2006," Agency for Healthcare Research and Quality, Rockville, MD, www.hcup-us.ahrq.gov/toolssoftware/ccs/ccs.jsp (accessed Oct. 26, 2009).
3. C. Kotwall, D. Covington, P. Churchill, C. Brinker, D. Weintritt, and J. G. Maxwell, "Breast conservation surgery for breast cancer at a regional medical center," *Am. J. Surg.* **176**, 510–514 (1998).
4. L. M. Apantaku, "Breast-conserving surgery for breast cancer," *Am. Fam. Physician* **66**, 2271–2278 (2002).
5. B. Jerome-D'Emilia and J. W. Begun, "Diffusion of breast conserving surgery in medical communities," *Soc. Sci. Med.* **60**, 143–151 (2005).
6. F. Fitzal and M. Gnant, "Breast conservation: evolution of surgical strategies," *Breast J.* **12**, S165–S173 (2006).
7. A. Luini, G. Gatti, S. Zurrada, N. Talakhadze, F. Brenelli, D. Gilardi, G. Paganelli, R. Orecchia, E. Cassano, G. Viale, C. Sangalli, B. Ballardini, G. R. dos Santos, and U. Veronesi, "The evolution of the conservative approach to breast cancer," *Breast* **16**, 120–129 (2007).
8. D. B. Kopans and S. DeLuca, "A modified needle-hookwire technique to simplify preoperative localization of occult breast lesions," *Radiology* **134**, 781 (1980).
9. D. B. Kopans, *Breast Imaging*, 3rd ed., Lippincott Williams & Wilkins, Philadelphia (2007).
10. S. Renton, J. Gazet, H. Ford, C. Corbishley, and R. Sutcliffe, "The importance of the resection margin in conservative surgery for breast cancer," *Eur. J. Surg. Oncol.* **22**, 17–22 (1996).
11. H. Luu, C. Otis, W. Reed, J. Garb, and J. Frank, "The unsatisfactory margin in breast cancer surgery," *Am. J. Surg.* **178**, 362–366 (1999).
12. E. Obedian and B. G. Haffty, "Negative margin status improves local control in conservatively managed breast cancer patients," *Cancer J. Sci. Am.* **6**, 28–33 (2000).
13. P. Tartter, J. Kaplan, I. Bleiweiss, C. Gajdos, A. Kong, S. Ahmed, and D. Zapetti, "Lumpectomy margins, reexcision, and local recurrence of breast cancer," *Am. J. Surg.* **179**, 81–85 (2000).
14. S. Singletary, "Surgical margins in patients with early-stage breast cancer treated with breast conservation therapy," *Am. J. Surg.* **184**, 383–393 (2002).
15. C. D. Scopa, P. Aroukatos, A. C. Tsamandas, and C. Aletra, "Evaluation of margin status in lumpectomy specimens and residual breast carcinoma," *Breast J.* **12**, 150–153 (2006).
16. C. Kotwall, M. Ranson, A. Stiles, and M. S. Hamann, "Relationship between initial margin status for invasive breast cancer and residual carcinoma after re-excision," *Am. Surgeon* **73**, 337–343 (2007).
17. V. G. Peters, D. R. Wyman, M. S. Patterson, and G. L. Frank, "Optical properties of normal and diseased human breast tissues in the visible and near infrared," *Phys. Med. Biol.* **35**, 1317–1334 (1990).
18. D. Grosenick, K. T. Moesta, H. Wabnitz, J. Mucke, C. Stroszczyński, R. Macdonald, P. M. Schlag, and H. Rinneberg, "Time-domain optical mammography: initial clinical results on detection and characterization of breast tumors," *Appl. Opt.* **42**, 3170–3186 (2003).
19. T. Durduran, R. Choe, J. P. Culver, L. Zubkov, M. J. Holboke, J. Giammarco, B. Chance, and A. G. Yodh, "Bulk optical properties of healthy female breast tissue," *Phys. Med. Biol.* **47**, 2847–2861 (2002).
20. T. Svensson, J. Swartling, P. Taroni, A. Torricelli, P. Lindblom, C. Ingvar, and S. Andersson-Engels, "Characterization of normal breast tissue heterogeneity using time-resolved near-infrared spectroscopy," *Phys. Med. Biol.* **50**, 2559–2571 (2005).
21. L. Spinelli, A. Torricelli, A. Pifferi, P. Taroni, G. M. Danesini, and R. Cubeddu, "Bulk optical properties and tissue components in the female breast from multiwavelength time-resolved optical mammography," *J. Biomed. Opt.* **9**, 1137–1142 (2004).
22. G. Zacharakis, A. Zolindaki, V. Sakkalis, G. Filippidis, T. G. Papanaglou, D. D. Tsiptsis, and E. Koumantakis, "In vitro optical characterization and discrimination of female breast tissue during near infrared femtosecond laser pulses propagation," *J. Biomed. Opt.* **6**, 446–449 (2001).
23. R. L. P. van Veen, H. J. C. M. Sterenborg, A. W. K. S. Marinelli, and M. Menke-Pluymers, "Intraoperatively assessed optical properties of malignant and healthy breast tissue used to determine the optimum wavelength of contrast for optical mammography," *J. Biomed. Opt.* **9**, 1129–1136 (2004).
24. A. Ishimaru, *Wave Propagation and Scattering in Random Media*, Vol. 1, Academic Press, New York (1978).
25. P. Moon and D. E. Spencer, *The Photonic Field*, MIT Press, Cambridge, MA (1981).
26. K. L. Hussman, B. A. Ward, C. F. McKhann, S. M. Pustilnick, I. Tocina, L. J. Horvath, L. E. Philpotts, and C. H. Lee, "Optical breast lesion localization fiber: preclinical testing of a new device," *Radiology* **200**, 865–866 (1996).